

# Nephrotoxic effect of Hydrogen Cyanamide (Dormex) and possible protective role of N-acetyl cysteine in male albino rats

Samah M. Elbastawesy<sup>1</sup>, Fatma MKh Ibrahim<sup>2</sup>, Hend S. Abo Safia<sup>2</sup>, Amira M. El Shamy<sup>3</sup>, Hoda A. Ibrahim<sup>3</sup>, and Nadia E. Helal<sup>1</sup>

<sup>1</sup> Forensic Medicine and Clinical Toxicology Department, Faculty of Medicine, Tanta University, Tanta, Egypt.

<sup>2</sup> Pathology Department, Faculty of Medicine, Tanta University, Tanta, Egypt.

<sup>3</sup> Medical Biochemistry and molecular biology Department, Faculty of Medicine, Tanta University, Tanta, Egypt.

## Abstract

**Background:** Dormex is a highly toxic fertilizer that causes local tissue irritation in addition to multiple organ toxicity mainly through oxidative stress. **Aim of the study:** This study aimed to investigate nephrotoxic effect of dormex and to evaluate potential protective role of N-acetyl cysteine (NAC) on kidney of male albino rats. **Methods:** This study was conducted on forty mature male albino rats were distributed to; Group I, II: rats were given normal saline and NAC, respectively. Group III: rats received single dose of dormex. Group IV: rats were given the same dose of dormex plus NAC. Blood urea and serum creatinine were assessed. Oxidative stress markers as malondialdehyde (MDA), catalase, reduced glutathione and superoxide dismutase (SOD) were measured. Renal specimens were studied with hematoxylin and eosin. **Results:** Renal indices, urea and creatinine, MDA were significantly increased, while glutathione reductase, catalase and glutathione peroxidase were lowered significantly in experimental rats received dormex. Kidney tissue of dormex administered rat's revealed tubulointerstitial nephritis, tubular necrosis and obstruction. Treatment with NAC markedly improved oxidative stress parameters but did not show marked effect on dormex induced histopathological changes. **Conclusions:** It can be concluded that dormex triggers oxidative stress causing affection of the renal function. Although NAC could decrease oxidative stress, it was not able to protect against cellular toxicity of dormex.

Received in original form: 3 November 2021

Accepted in a final form: 15 August 2022

## Key words

Hydrogen cyanamide, Dormex, nephrotoxicity, Acetyl cysteine, oxidative stress

## Introduction

More than 150,000 people die annually from pesticide poisoning. Pesticide poisoning may be self-induced by ingestion, occupational or accidental exposures. Owing to its availability, pesticide poisoning commonly reported in rural areas of low and mid-income countries (Eddleston, 2020). Although there are many reports on pesticide toxicity, reports of dormex poisoning are scarce (Inamadhar and Palit, 2007). Hydrogen Cyanamide (Dormex), is a nitrogen fertilizer specially for grapes in addition to its herbicidal and fungicidal effects. It is used in agriculture by spraying to accelerate the buds break (Sudawan et al., 2016). In some countries of Europe, Canada and Japan, Cyanamide has been approved to be used in treatment of chronic alcoholism (Ibrahim et al., 2015). The usual methods of exposure to dormex occur through inhalation, dermal contact or ingestion. Absorption occurs rapidly through all routes (Foti et al., 2008). There are no reports about conversion of hydrogen cyanamide to cyanide in vivo (Mertschenk et al. 1991). The bioavailability of dormex ranges from (45-80%) depending mainly on the dose (Schep et al., 2009). Just about 40% of oral dose is excreted in urine during the first 24 hours. The main metabolite excreted

in the urine is *N*-acetylcyanamide. While the remaining either excreted in stool or exhaled finally as carbon dioxide (Oreby et al., 2015). The U.S. Environmental Protection Agency (EPA) has placed dormex in chemicals with highest toxicity category (toxicity category I) (Cochran et al., 1993). Dormex product is severely toxic product with rat oral LD 50 of 300mg/kg and dermal LD50 of 1700mg/kg (El Masry et al., 2000).

The exact mechanism of toxicity of dormex is not known (Settimi et al., 2007). Studies suggested that dormex induces oxidative stress through catalase inhibition. Inhibition of catalase resulted in oxidative stress and uncoupling of oxidative phosphorylation (de Zwart et al., 1999; El Masry et al., 2000). Oxidative stress is known to cause hepatic, renal, and lung damage. Central nervous system, cardiovascular system, and hemopoietic system are also apparently affected (Gamaluddin et al., 2012). Dormex also suggested causing parasympathetic over-activity. In addition, it inhibits aldehyde dehydrogenase enzyme, which explains its use in treatment of chronic alcoholism (El Mahdy and Kharoub, 2020).

Dormex is reported to cause serious clinical manifestations as headache, hypotension, palpitation, respiratory distress, vomiting, disulfiram-like reaction in addition to skin and ocular irritation (Sharif and Fayed, 2021). Marked hepatotoxic effect of acute dormex exposure has been reported in many patients with noticeable elevation of liver enzymes together with affection of other liver function as PT and bilirubin level. Considerable elevation of serum creatinine has been recorded in some patients with acute hydrogen cyanamide poisoning (Gamaluddin et al., 2012; El Mahdy and Kharoub, 2020; Sharif and Fayed, 2021). The main mechanism of nephrotoxicity of dormex is not yet known. Some research referred this to either direct toxic effect of dormex or to the severe hypotension and shock induced by it (Xie et al., 2010). Previous animal studies have mainly focused upon hepatotoxicity of dormex, but to our knowledge there is limited number of research on dormex induced nephrotoxicity.

N-acetyl cysteine (NAC) is a mucolytic drug that facilitates clinging mucous secretions and augments glutathione S-transferase activity. It is known also with its powerful antioxidant properties. It is widely used as treatment option for diseases associated with generation of free radicals (Shahin et al., 2009). The antioxidant effect of NAC is due to its role as a glutathione precursor, which is one of the most essential naturally occurring antioxidants (Elgindy et al., 2010). The suggested mechanism of dormex induced organ toxicity is free radical production.

### Aim of the Study

Aim of the current Study is to investigate nephrotoxic effect of dormex and to evaluate potential protective role of NAC on kidney of male albino rats.

## Animals and Methods

### Experimental rats:

Forty adult male albino rats, weighing 150-200 g, were obtained from the animal house of the Faculty of Medicine, Tanta University. They were kept in standard conditions for laboratory rats for one week in wire mesh cages and had free access to water and fed on the standard diet (Reeves et al., 1993). They were exposed to 12:12 hours light/ dark cycles and room temperature between 22 and 24 °C. Prior to the experiment, animals were deprived from food for 24 hours to ensure an empty stomach (only water was allowed).

### Compliance with ethical standards

The study was carried out according to the guide of care and the use of laboratory animals approved by the Ethical Committee of Faculty of Medicine, Tanta University, (approval number: 34464/2/21). The minimum estimated number of animals to offer valid results was used.

### Chemicals, kits, and drugs

Dormex: (Hydrogen cyanamide 50% w/w) was produced by Ningxia Darong chemicals & Metallurgy Co. LTD, China and purchased from Ind. Consult, Cairo in the form of 5 liters suspension. All chemicals and kits with high analytical grade were

purchased from Bio-diagnostic Company (Cairo, Egypt).

### Experimental design

Rats were acclimatized under standard laboratory conditions for one week before the experiment started. Rats were then randomly distributed into 4 groups (n=10 in each group).

Group I (Control): 10 rats received 1 ml of 0.9% saline (the same dose was used to dissolve dormex and NAC) via an oral cannula for 5 consecutive days.

Group II: 10 rats received NAC (150 mg/kg) (Yurumez et al., 2007) by gavage needle for 5 days. NAC was dissolved in saline immediately before administration.

Group III: 10 rats received a single oral administration of dormex (100 mg/kg body weight suspended in 1 mL saline) (1/3 LD50) (Meister, 1994; El Masry et al., 2000) via an oral cannula at the end of the 4th day. Dormex is well known to cause local corrosive effect on tissues it comes in contact with (Sharif and Fayed, 2021). Rats were treated by intra- peritoneal injection of 25mg/kg of acetaminophen in a volume of 10 mg/ml (Acetaminophen, Perfalgan®, BMS Pharmaceutical, Italy) to overcome pain (Im et al., 2012).

Group IV: 10 rats received NAC in the same dose as group II (for 5 days) plus single oral dose of 100 mg/kg dormex (1/3 LD50) (Meister, 1994; El Masry et al., 2000) concomitantly at the 4<sup>th</sup> day of the experiment. These preparations will be given orally by oral cannula. Rats were treated by intra- peritoneal injection of 25mg/kg of acetaminophen as group III to overcome pain.

### Sample collection:

After the experimental period (after 5<sup>th</sup> day of start of the experiment), the animals in the different groups were anesthetized (by ether inhalation) and sacrificed. Blood was collected from the heart by direct cardiac puncture, and then was centrifuged at 1500 rpm for 15 minutes at an ambient temperature. The collected blood was then divided into two different tubes i.e., one with anticoagulant for plasma separation and another without anticoagulant to separate serum and stored at -80 °C until used for biochemical measurements. The kidneys from all experimental groups were removed through a median abdominal incision.

### Biochemical Analysis:

- Biochemical determination of the levels of urea and creatinine was estimated spectrophotometrically according to the standard procedures using commercially available diagnostic kits (biodiagnostic company, Cairo, Egypt.)
- The lipid peroxidation indices, including, malondialdehyde (MDA) measurement at 534 nm using the thiobarbituric acid reactive substances (TBARS) method (Ohkawa et al., 1979). Glutathione reductase assay was determined by measuring the rate of oxidation to NADP<sup>+</sup>, which is associated by a decline in absorbance at 340 nm using commercial kit (Goldberg and Spooner, 1983). Catalase activity was estimated spectrophotometrically at 240 nm by using Claiborne method (Claiborne, 1985). SOD activity was estimated spectrophotometrically according to

the methods of Kakkar et al., (1984). Determination of glutathione peroxidase (Gpx) activity according to the methods of Rotruck et al., (1973).

#### • Tissue preparation:

Dissected kidneys were washed and weighed. Then each kidney was divided into two parts. The first portion was weighed and homogenized with a potter-Elvehjem tissue homogenizer in phosphate buffer saline (PBS) 10 mM pH 7.4 and centrifuged. The supernatant was used for the biochemical analysis for determination of MDA levels, glutathione reductase and catalase activities. The second part was specimen was submerged directly in 10% neutral-buffered formalin for histopathological examination.

#### Histopathological examination

Part of kidneys of different groups were removed and fixed in 10% formalin solution for 24 hours. Specimens were then routinely processed with dehydration in ascending grades of alcohol followed by clearing in xylene and paraffin wax embedding. Sections of 4µm thickness were cut, mounted into glass slides and stained by hematoxylin and eosin (Bancroft and Gamble, 2008). Sections were examined by two pathologists blinded of the different groups. The hematoxylin-eosin sections were then photographed using Olympus light microscope (Olympus BX51, Tokyo, Japan).

#### Statistical Analysis

Statistical analysis in this study was performed using SPSS version 23. Basic and clinical variables are mentioned as mean  $\pm$  SD for the quantitative variables, and are summarized using frequency (percentage) for the categorical variables. ANOVA test was applied to compare variables between 4 groups. All statistical tests were two-tailed and only a P value  $\leq 0.05$  was considered statistically significant.

## Results

#### Biochemical results

##### *Effect of dormex and NAC on kidney function markers (urea and creatinine)*

Comparison between the studied groups as regards studied renal indices revealed that there was statistically significant increase in values of (Urea, Creatinine) in group III & IV in comparison to group I & II. However, this increase was significantly higher in group III in comparison to group IV (**Table 1**).

##### *Effect of dormex and NAC on oxidative stress parameters and total antioxidants parameters*

Malondialdehyde (MDA) was significantly increased in group III & IV in comparison to group I & II. However, this increase was significantly higher in group III in comparison to group IV ( $P < 0.05$ ). There was significant decrease in (Superoxide dismutase (SOD), reduced glutathione, catalase and Glutathione peroxidase (Gpx)) in group III & IV. There was a statistically significant difference in its values among all groups ( $P < 0.05$ ). There was insignificant difference between group I & II. However, there was significant increase of these antioxidants parameters in group IV compared to group III (**Table 1**).

There was statistically significant increase in values of renal (MDA) in group III & IV in comparison to group I & II. In addition, this oxidative stress marker was significantly higher in group III than group IV ( $P < 0.05$ ). Yet, there was significant decrease in renal reduced glutathione & catalase in group III & IV with additional significant difference between both groups ( $P < 0.05$ ) and insignificant difference between group I & II (**Table 2**).

##### *Histopathology effect of dormex and NAC*

Examination of renal tissue sections from the control group (Group I) and NAC only receiving rats (Group II) showed unremarkable changes with no evidence of pathological lesions **Figure (1)**.

While Examination of renal tissue sections from the rats receiving dormex only (Group III) revealed generalized vascular congestion besides areas of interstitial and intratubular hemorrhage was seen. Moreover, renal tubules and collecting ducts exhibited features of severe injury including tubular necrosis with detachment of tubular and collecting duct epithelium from their basement membrane. Also, occlusion of tubular lumina by casts and sloughed necrotic cells was obvious in many tubules. Perivascular mononuclear cellular infiltrate with evidence of tubule-interstitial nephritis was also detected. Besides, some glomeruli exhibited fibrin microthrombi and ischemic sclerotic changes **Figures (2&3)**. Sections from kidney tissue of rats receiving both dormex and NAC revealed no or very mild improvement of pathological features, with Persistence of interstitial hemorrhage and tubular necrosis **Figures (4)**.

**Table (1): ANOVA one-way statistical analysis of biochemical kidney function parameters and oxidant/antioxidant biomarkers among the studied groups in blood samples**

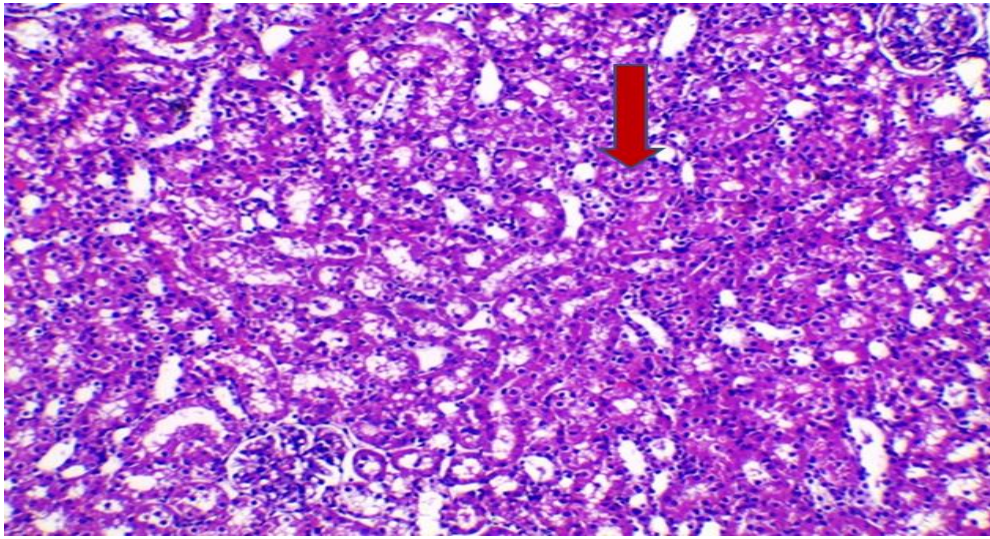
Parameters		Groups				ANOVA	
		Group I (n=10)	Group II (n=10)	Group III (n=10)	Group IV (n=10)	F	P-value
<b>Creatinine ( mg/dl )</b>	<b>Mean ± SD</b>	0.345± 0.016 <sup>cd</sup>	0.367 ± 0.015 <sup>cd</sup>	0.875 ± 0.036 <sup>abd</sup>	0.725±.0378 <sup>abc</sup>	876.59	<0.001*
<b>Urea ( g/dl )</b>	<b>Mean ± SD</b>	24.38±0.924 <sup>cd</sup>	25.86±0.864 <sup>cd</sup>	64.37±1.11 <sup>abd</sup>	47.01±1.43 <sup>abc</sup>	3214.71	<0.001*
<b>MDA (nmol/ml)</b>	<b>Mean ± SD</b>	8.72 ±0.13 <sup>cd</sup>	8.67. ±0.22 <sup>cd</sup>	15.68±0.36 <sup>abd</sup>	12.9±0.26 <sup>abc</sup>	738.16	<0.001*
<b>SOD ( u/ml)</b>	<b>Mean ± SD</b>	7.22 ±0.304 <sup>cd</sup>	6.932±0.249 <sup>cd</sup>	3.252±0.188 <sup>abd</sup>	4.84±0.250 <sup>abc</sup>	553.76	<0.001*
<b>Reduced glutathione (mg /ml)</b>	<b>Mean ± SD</b>	39.8±1.317 <sup>cd</sup>	38.93±1.267 <sup>cd</sup>	18.20±0.788 <sup>abd</sup>	27.80±0.788 <sup>abc</sup>	914.44	<0.001*
<b>Catalase (u/ml)</b>	<b>Mean ± SD</b>	31.41±0.202 <sup>cd</sup>	30.81±0.791 <sup>cd</sup>	12.161±0.247 <sup>abd</sup>	22.37±0.125 <sup>abc</sup>	2723.53	<0.001*
<b>Gpx (U/ml)</b>	<b>Mean ± SD</b>	8.22±0.587 <sup>cd</sup>	8.65±0.369 <sup>cd</sup>	5.01±0.185 <sup>abd</sup>	7.26±0.323 <sup>abc</sup>	170.37	<0.001*

*n*: number, (MDA): Malondialdehyde, (SOD): Superoxide dismutase, (Gpx): Glutathione peroxidase, SD: standard deviation, a–d Significant difference between groups at \**p* < 0.05. a: significance from group I; b: significance from group II; c: significance from group III; d: significance from group IV, F: ANOVA one-way statistical analysis.

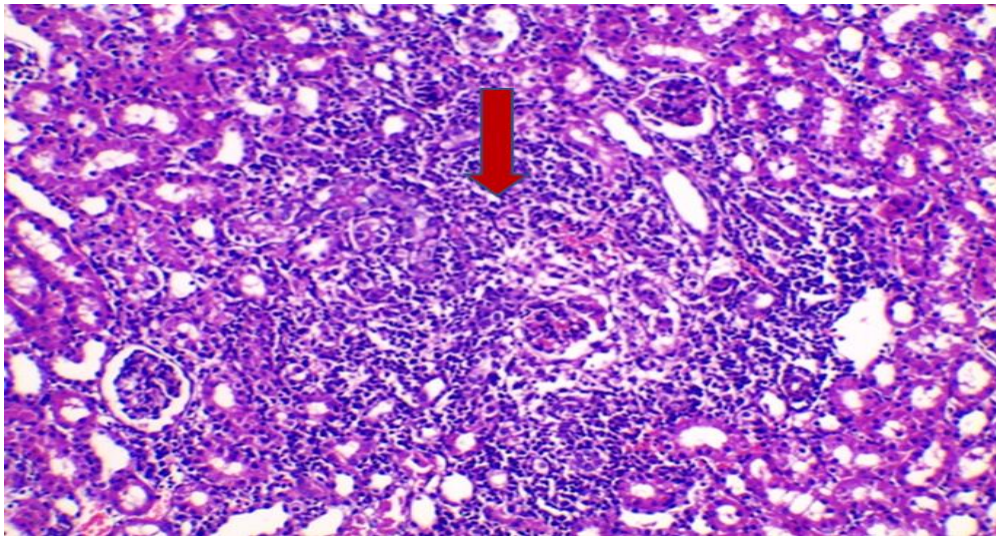
**Table (2): ANOVA one-way statistical analysis of oxidant/antioxidant biomarkers among the studied groups in renal tissue:**

Parameters		Groups				ANOVA	
		Group I (n=10)	Group II (n=10)	Group III (n=10)	Group IV (n=10)	F	P-value
MDA (nmol/gm tissue)	<b>Mean±SD</b>	9.65±0.48 <sup>cd</sup>	10.25± 0.836 <sup>cd</sup>	19.12± 1.399 <sup>abd</sup>	14.88±0.262 <sup>abc</sup>	265.37	<0.001*
Reduced glutathione (mg /gm tissue )	<b>Mean±SD</b>	42.8±1.033 <sup>cd</sup>	42.1±0.738 <sup>cd</sup>	21.0±0.817 <sup>abd</sup>	30.85±1.187 <sup>abd</sup>	1170.81	<0.001*
Catalase (u\gm tissue)	<b>Mean±SD</b>	33.70±1.268 <sup>cd</sup>	33.06±0.892 <sup>cd</sup>	15.76±0.237 <sup>abd</sup>	25.02±0.239 <sup>abc</sup>	1121.53	<0.001*

*n*: number, (MDA): Malondialdehyde, (SD: standard deviation, <sup>a–d</sup> Significant difference between groups at \**p* < 0.05. a: significance from group I; b: significance from group II; c: significance from group III; d: significance from group IV, F: ANOVA one-way statistical analysis.

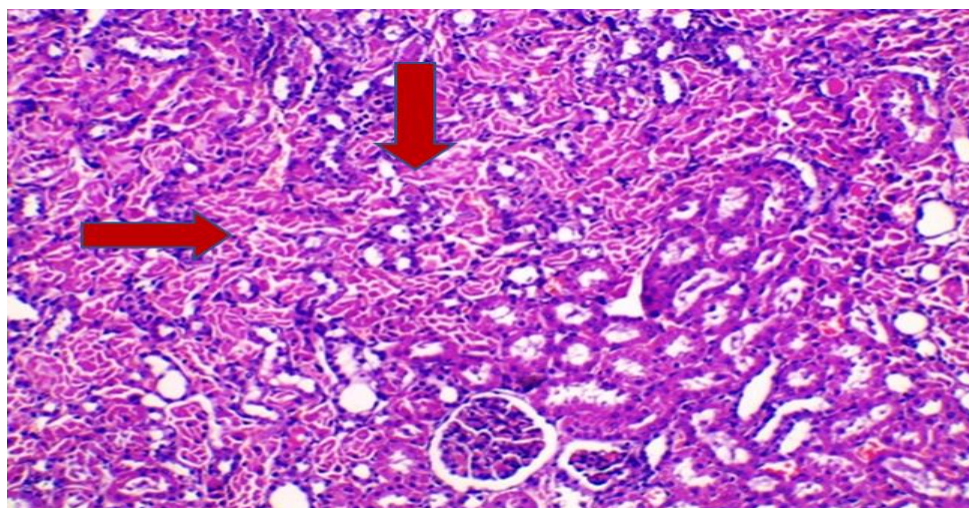


**Figure 1: Transverse section of group II rat's kidney (N acetyl cysteine only) showed near normal closely packed renal tubules (red arrow) lined by continuous cuboidal and low columnar epithelium (H&E X200)**

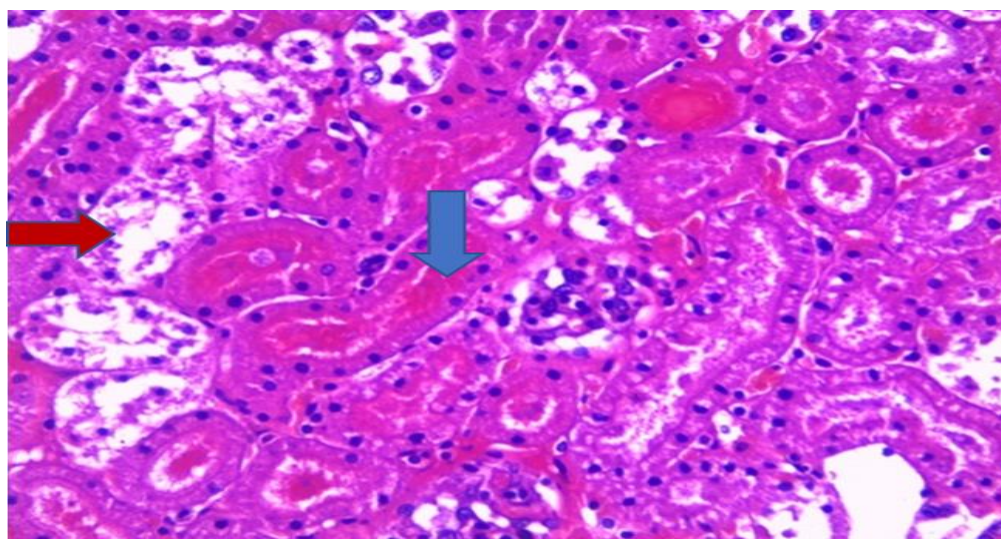


**Figure 2: Transverse section of group III rat's kidney (dormex group) showed marked tubule-interstitial nephritis with mononuclear inflammatory infiltrate in between renal tubules (read arrow) (H&E X200)**





**Figure 3: Transverse section of group III rat's kidney (dormex group) showed wide areas of tubular necrosis (red arrows) (H&E X200)**



**Figure 4: Transverse section of group IV rat's kidney (N acetyl cysteine plus dormex) revealed wide areas of tubular necrosis with areas of interstitial and intratubular hemorrhage (blue arrow). Tubular lumina are occluded by haemorrhage and detached necrotic epithelial cells (red arrow) (H&EX200)**

## Discussion

The kidney is an organ susceptible to damaging effects of drugs or toxicants probably due to larger perfusion and higher concentration of compounds excreted in renal tubular cells (Mohamed et al., 2003). The main objective of the current study is to investigate the nephrotoxic effect of dormex on adult male albino rats and to evaluate possible protective role of NAC on kidney tissue. The result of the study revealed that acute dormex exposure induce nephrotoxicity in studied animals, which was evident by significant increase in urea and creatinine in group III and IV who received either dormex alone or combination of dormex and NAC. Yet, mean urea and creatinine level were significantly lowered in group IV than group III. This increase in urea and creatinine induced by dormex comes in accordance with results of El Masry et al., (2000). In previous clinical research on patients acutely intoxicated with dormex, evident nephrotoxicity was reported manifested by increase serum creatinine and blood urea level (Gamaluddin et

al., 2012; Sharif and Fayed, 2021). Makris and Spanou, (2016) allocated that increased serum creatinine indicates renal injury and even at certain levels renal failure. This renal injury may be due to oxidative stress induced by dormex. Oxidative stress associated with excessive formation of free radicals and boosted lipid peroxidation resulting in renal tissue damage (Lobo et al., 2010). In the current study, parameters of oxidative stress in group III and IV demonstrated significant increase of MDA while the opposing antioxidants; SOD, reduced glutathione, catalase and glutathione peroxidase were significantly decreased. These results agree with findings of Elhosary et al., (2018). Superoxide dismutase is a metalloprotein usually involved as the first antioxidant enzyme which start lowering the steady state level of oxygen free radicals (McCord et al., 1971). Catalase is a heme protein catalyzes hydroperoxide to water and oxygen and protects the cell from its oxidative damage (Chance et al., 1952). Glutathione peroxidase catalyzes the

reaction between hydroperoxide and total glutathione to form hydroperoxide (Freeman and Crapo, 1982). In our study, fall in the activities of these enzymes in dormex-administered rats ascertains that lipid peroxidation and oxidative stress are provoked by dormex intoxication. Previous studies concluded that, cyanamide is activated by catalase enzyme, which sequentially causes catalase inhibition. Inhibition of catalase in turn leads to uncoupling of oxidative phosphorylation together with inhibition of adenosine nucleotide synthesis. This result in formation of free radicals and finally increasing oxidative stress (Ibrahim et al., 2015). There was increase in activity of superoxide dismutase, catalase and glutathione peroxidase in group IV. This increase may result from effect of NAC, scavenging of radicals generated by dormex induced lipid peroxidation. This led to decrease in utilization of these antioxidant enzymes in the oxidative stress induced by dormex. It is therefore assumed that toxicity of poisons that induce oxidative stress could be decreased by using antioxidants (Mukherjee et al., 2013). N-acetyl cysteine act as a sulfhydryl groups donor which the cells use to produce metabolites capable of stimulating GSH synthesis. IT also acts as a free radical scavenger and protect against oxidative stress (Tobwala et al., 2015).

The histopathological observations in dormex treated rat's kidneys (group III) revealed injury of renal tissue evidenced by presence of generalized vascular congestion with areas of interstitial and intratubular hemorrhage. Renal tubules and collecting ducts exhibited features of severe injury including tubular necrosis with evidence of tubule-interstitial nephritis. Near similar histopathological results were previously reported by El Masry et al., (2000). Besides, some glomeruli exhibited fibrin microthrombi and ischemic sclerotic changes. This picture is similar to histopathological changes caused by some poisons as Viper snakes (Willinger et al., 1995). Unfortunately, these histopathological changes were not affected by combined NAC administration in group IV in spite that El Masry et al., (2000) reported that another antioxidant (Tocopherol (Vitamin E)) was able to improve oxidative stress and histopathological changes caused by dormex. The in ability of NAC to improve histopathological changes would be explained that oxidative damage may not be the only mechanism dormex induce organ toxicity. Ischemic findings and DIC in the current study may play additional role. Adding to this, other researchers referred nephrotoxicity of dormex may be due to either its direct toxic effect or to severe hypotension and shock induced by it (Xie et al., 2010).

## Conclusion

Cyanamide triggers oxidative stress which causes affection of the renal function. Although NAC could decrease oxidative stress, it was not able to protect against cellular toxicity of dormex.

## Recommendations

It's highly recommended to study multi- organ toxicity induced by dormex. Suggestion of repetition of

the current study with using either another antioxidants or medication known for its Reno-protective properties in a trial to identify new medications that could be used as an adjuvant therapy in dormex intoxicated patients.

## References

- Bancroft JD and Gamble M (2008): Theory and Practice of Histological Techniques. 6<sup>th</sup> ed. China: Elsevier.
- Chance B, Greenstein D. and Roughton FJW (1952): The mechanism of catalase action. I. Steady-state analysis. Archives of biochemistry and biophysics, 37(2):301–321.
- Claiborne A (1985): Catalase activity. In: CRC Handbook of Methods for Oxygen Radical Research. Boca Raton: CRC Press, pp 283–284.
- Cochran RC, Leung P, Moore TB, et al. (1993): Hydrogen Cyanamide: Risk Characterization Document. California Environmental Protection Agency. Available at: <http://citeseerx.ist.psu.edu/viewdoc/download;jsessionid=5E23F89C3DBB9CF41367B105B7833E03?doi=10.1.1.641.4254&rep=rep1&type=pdf>. accessed at 21 January 2021.
- de Zwart LL, Vermeulen NP, Hermanns RC, et al. (1999): Urinary excretion of biomarkers for radical-induced damage in rats treated with NDMA or diquat and the effects of calcium carbimide co-administration. Chemico-biological interactions, 117(2):151–172.
- Eddleston M (2020): Poisoning by pesticides. Medicine 48:214–217.
- El Mahdy NM and Kharoub HS (2020): Acute toxicity due to occupational exposure to the plant growth regulator hydrogen cyanamide (case report). Egyptian Journal of Occupational Medicine, 44(1):471–484.
- El Masry M, Osman H and Hady A (2000): Cyanamide Toxicity. Role of Alpha Tocopherol Antioxidant. New Egyptian journal of medicine. Available at: [https://www.researchgate.net/publication/232088361\\_Cyanamide\\_Toxicity\\_Role\\_of\\_Alpha\\_Tocopherol\\_Antioxidant](https://www.researchgate.net/publication/232088361_Cyanamide_Toxicity_Role_of_Alpha_Tocopherol_Antioxidant)
- Elgindy EA, El-Huseiny AM, Mostafa MI, et al. (2010): N-acetyl cysteine: could it be an effective adjuvant therapy in ICSI cycles? A preliminary study. Reproductive biomedicine online, 20(6):789–796.
- Elhosary N, Elgharbawy DE, Kassab A, et al. (2018): Cyanamide-Induced Hepatotoxicity and the Potential Protective Role of Pomegranate Seed Extract in Adult Male Albino Rats. Ain Shams Journal of Forensic Medicine and Clinical Toxicology, 30(1):38–51.
- Foti C, Bonamonte D, Conserva A, et al. (2008): Allergic contact dermatitis with a fertilizer containing hydrogen cyanamide (Dormex). Cutaneous and ocular toxicology, 27(1):1–3.
- Freeman BA and Crapo JD (1982): Biology of disease: free radicals and tissue injury. Laboratory investigation; a journal of technical methods and pathology, 47(5):412–426.

- Gamaluddin H, Mahmood S, Mosa M, et al. (2012): A Clinical Study of Acute Hydrogen Cyanamide Toxicity in the Period between 2006-2009 in the Poison Control Center, Ain Shams University. *Ain Shams Journal of Forensic Medicine and Clinical Toxicology*, 19:97-103.
- Goldberg DM and Spooner RJ (1983): Glutathione reductase. In: Bergmeyer HV (ed) *Methods of Enzymatic Analysis*, 3<sup>rd</sup> edn. Deerfield beach: Verlag Chemie, pp 258-265.
- Ibrahim MAA, Elmadah EI and Hafez ASAF (2015): Toxic Effect of Hydrogen Cyanamide and the Possible Protective Effect of Selenium on Exocrine Pancreas of Adult Male Albino Rats. *Egypt Journal of Forensic Science and Applied Toxicology*, 15:225-245.
- Im KS, Jung HJ, Kim JB, et al. (2012): The antinociceptive effect of acetaminophen in a rat model of neuropathic pain. *The Kaohsiung journal of medical sciences*, 28(5):251-258.
- Inamadar A and Palit A (2007): Cutaneous reactions simulating erythema multiforme and Stevens Johnson syndrome due to occupational exposure to a plant-growth regulator. *Indian journal of dermatology, venereology and leprology*, 73(5):330-332.
- Kakkar P, Das B and Viswanathan PN (1984): A modified spectrophotometric assay of superoxide dismutase. *Indian journal of biochemistry & biophysics*, 21(2):130-132.
- Lobo V, Patil A, Phatak A, et al. (2010): Free radicals, antioxidants and functional foods: Impact on human health. *Pharmacognosy reviews*, 4(8):118.
- Makris K and Spanou L (2016): Acute Kidney Injury: Definition, Pathophysiology and Clinical Phenotypes. *The Clinical biochemist. Reviews*, 37(2):85-98.
- McCord JM, Keele BB and Fridovich I (1971): An enzyme-based theory of obligate anaerobiosis: the physiological function of superoxide dismutase. *Proceedings of the National Academy of Sciences of the United States of America*, 68(5):1024-1027.
- Meister (1994): *Farm chemicals handbook '94*, 1<sup>st</sup> ed. Willoughby OH USA: Meister publishing company.
- Mertschen B, Bornemann W, Filser JG, et al. (1991): Urinary excretion of acetylcyanamide in rat and human after oral and dermal application of hydrogen cyanamide (H<sub>2</sub>NCN). *Archives of toxicology*, 65(4):268-272.
- Mohamed M, Abdel Latif MD, Sahar A, et al. (2003): Sodium fluoride ion and renal function after prolonged sevoflurane or isoflurane anaesthesia. *European Journal of Anaesthesiology*, 19:79-83.
- Mukherjee S, Ghosh S, Choudhury S, et al. (2013): Pomegranate reverses methotrexate-induced oxidative stress and apoptosis in hepatocytes by modulating Nrf2-NF- $\kappa$ B pathways. *The Journal of nutritional biochemistry*, 24(12):2040-2050.
- Ohkawa H, Ohishi N and Yagi K (1979): Assay for lipid peroxides in animal tissues by thiobarbituric acid reaction. *Analytical biochemistry*, 95(2):351-358.
- Oreby MM, Elgazzar FM and El-Nabi SEH (2015): The toxic effect of cyanamide (dormex) on testis in albino rats: possible protective role of selenium. *Egypt Journal of Forensic Science and Applied Toxicology*, 15:205-223.
- Reeves PG, Nielsen FH and Fahey GC (1993): AIN-93 purified diets for laboratory rodents: final report of the American Institute of Nutrition ad hoc writing committee on the reformulation of the AIN-76A rodent diet. *The Journal of nutrition*, 123(11):1939-1951.
- Rotruck JT, Pope AL, Ganther HE, et al. (1973): Selenium: biochemical role as a component of glutathione peroxidase. *Science (New York, N.Y.)*, 179(4073):588-590.
- Schep L, Temple W and Beasley M (2009): The adverse effects of hydrogen cyanamide on human health: an evaluation of inquiries to the New Zealand National Poisons Centre. *Clinical toxicology (Philadelphia, Pa.)*, 47(1):58-60.
- Settimi L, Davanzo F, Travaglia A, et al. (2007): Italian Program for Surveillance of Acute Pesticide-Related Illnesses: cases identified in 2005. *Giornale italiano di medicina del lavoro ed ergonomia*, 29(3): 264-266.
- Shahin AY, Hassanin IMA, Ismail AM, et al. (2009): Effect of oral N-acetyl cysteine on recurrent preterm labor following treatment for bacterial vaginosis. *International Federation of Gynaecology and Obstetrics*, 104(1):44-48.
- Sharif AF and Fayed MM (2021): Evaluation of Multiple Organ Dysfunction Score (MODS) and the Sequential Organ Failure Assessment (SOFA) score as in-hospital outcome predictors among cases of hydrogen cyanamide exposure: a cross-sectional study. *Environmental science and pollution research international*, 28(31):42161-42176.
- Sudawan B, Chang CS, Chao H, et al. (2016): Hydrogen cyanamide breaks grapevine bud dormancy in the summer through transient activation of gene expression and accumulation of reactive oxygen and nitrogen species. *BMC plant biology*, 16(1):202.
- Tobwala S, Khayyat A, Fan W, et al. (2015): Comparative evaluation of N-acetylcysteine and N-acetylcysteineamide in acetaminophen-induced hepatotoxicity in human hepatoma HepaRG cells. *Experimental biology and medicine (Maywood, N.J.)*, 240(2):261-272.
- Willinger CC, Thamaree S, Schramek H, et al. (1995): In vitro nephrotoxicity of Russell's viper venom. *Kidney international*, 47(2):518-528.
- Xie G, Zheng X, Qi X, et al. (2010): Metabonomic evaluation of melamine-induced acute renal toxicity in rats. *Journal of proteome research*, 9(1):125-133.



Yurumez Y, Cemek M, Yavuz Y, et al. (2007):  
Beneficial effect of N-acetylcysteine against  
organophosphate toxicity in mice. Biological &  
pharmaceutical bulletin, 30(3):490-494.

## التأثير الكلى السام للهيدروجين سيناميد (دورمكس) والدور الوقائي المحتمل للـ إن أستيل سستاين في ذكور الجرذان البيضاء

سماح ماهر البسطويسى<sup>١</sup> و فاطمة خيرى إبراهيم<sup>٢</sup> و هند صلاح أبو صفة<sup>٣</sup> و أميرة مصطفى الشامى<sup>٢</sup> و هدى على إبراهيم<sup>٢</sup> نادية عزت هلال<sup>١</sup>

### الملخص العربي

**المقدمة:** يعتبر الدورمكس من الأسمدة ذات السمية العالية حيث يسبب تهيج الأنسجة الموضعي بالإضافة إلى تأثيره السام على العديد من أجهزة الجسم المختلفة وذلك من خلال الإجهاد التأكسدي الذي يحدثه.

**الهدف من البحث:** الهدف من هذا البحث هو التحقق من التأثير الكلى السام للدورمكس وتقييم الدور الوقائي المحتمل للـ إن أستيل سستاين على الكلية في ذكور الجرذان البيضاء.

**طريقة البحث:** أجريت هذه الدراسة على أربعين من ذكور الجرذان البيضاء الناضجة وزعت على أربع مجموعات المجموعة الأولى والثانية: أعطيت الفئران المحلول الملحي و إن أستيل سستاين على التوالي. المجموعة الثالثة تم إعطاؤها جرعة واحدة من الدورمكس. المجموعة الرابعة: تم إعطاؤها جرعة واحدة من الدورمكس بالإضافة إلى الأستيل سستاين كالمجموعة الثانية. تم تقييم وظائف الكلى عن طريق قياس يوريا الدم ومصل الكرياتينين. وكذلك تم قياس بعض علامات الإجهاد التأكسدي مثل مالونداى الدهايد والكاتاليز والجلوتاثيون المختزل والدميوتاز فائق الأكسدة، وتم فحص عينات باثولوجية من الكلى بعد صبغها بالهيماتوكسيلين والأيوسين.

**النتائج:** لوحظ تأثير وظائف الكلى، وزيادة اليوريا والكرياتينين، ومالونداى الدهايد بشكل ملحوظ، بينما انخفضت نسبة الجلوتاثيون المختزل، الكاتالاز والجلوتاثيون بيروكسيداز بشكل كبير في الفئران التجريبية التي تم إعطاؤها الدورمكس. وأظهرت الأنسجة الكلوية لتلك الفئران التهاب الكلية الخلالي الأنبوبي ونخر الأنببيب وانسدادها. وقد لوحظ أن علاج الفئران بالإن أستيل سستاين في المجموعة الرابعة قد أظهر تحسن في علامات الإجهاد التأكسدي ولكن لم يظهر تأثير ملحوظ على التغيرات النسيجية التي سببها الدورمكس.

**الاستنتاج:** يمكن الاستنتاج بأن الدورمكس يسبب الإجهاد التأكسدي الذي يؤثر سلباً على وظائف الكلى. على الرغم من قدرة الإن أستيل سستاين على تقليل ذلك الإجهاد التأكسدي، إلا أنه لم يكن قادراً على الحماية من التسمم الخلوى الذى سببه الدورمكس على الكلية.

١. مدرس الطب الشرعى والسموم الإكلينيكية . كلية الطب . جامعة طنطا

٢. مدرس الباثولوجي . كلية الطب . جامعة طنطا

٣. مدرس الكيمياء الحيوية الطبية . كلية الطب . جامعة طنطا